



## PATHOGENICITY OF *EIMERIA* SPECIES ISOLATED FROM CHICKEN IN THUA THIEN HUE PROVINCE

Ho Thi Dung<sup>1,\*</sup>, Pham Hoang Son Hung<sup>1</sup>, Nguyen Thi Thao<sup>1</sup>, Nguyen Đang Qui<sup>2</sup>,  
Nguyen Đinh Thuy Khuong<sup>1</sup>, Phan Vu Hai<sup>1</sup>

<sup>1</sup> University of Agriculture and Forestry, Hue University, 102 Phung Hung St., Hue, Vietnam

<sup>2</sup> Institute of Biotechnology, Hue University, Road 10, Phu Vang, Thua Thien Hue, Vietnam

**Abstract:** The present study clarifies the effect of locally isolated *Eimeria* species on chickens in central Vietnam. Oocysts of *Eimeria* species were isolated from feces suspected to be infected with coccidiosis in 3 farms in Huong Thuy district, Thua Thien Hue province. A total of 54 2-week-old chickens were randomly allocated to 2 groups: 3 replicates containing 9 chickens in each replicate. The chicken in group 1 were orally inoculated with  $2 \times 10^4$  isolated oocysts of *Eimeria* species, while the chickens in group 2 were inoculated with PBS as a control. Growth performance, oocyst output, gross lesions, and histopathological lesions were measured at 5, 10 and 28 days after infection. The chicks in group 1 showed general signs of ruffled feathers, anorexia, huddling together with diarrhea and/or bloody dropping from 4-7 days post-infection. Feed intake, growth performance and body weight in group 1 were lower than those of the control chicks. The oocyst was detected in the feces of chicks in group 1 from 6-14 days post-infection, among them, the number of oocysts reach the peak at 8 days post-infection. At day 5 post-infection, the most damaged part of the intestine is the ceca with a large amount of blood in the ceca content. The histopathological lesions were detected clearly by HE staining at day 5 and 10 post-infection. In conclusion, the locally isolated oocysts of *Eimeria* species have high virulence to the chickens. The present study provides useful information related to the pathogenicity of *Eimeria* species which may contribute to coccidiosis diagnosis and treatment in poultry production.

**Keywords:** *Eimeria*, coccidiosis, infection, central Vietnam

### 1 Introduction

Coccidiosis is one of the most important diseases in the poultry industry caused by *Eimeria*, a protozoan parasite genus consisting of 9 species: *Eimeria praecox*, *E. aceroulina*, *E. mitis*, *E. mivati*, *E. hagani*, *E. maxima*, *E. brunetti*, *E. tenella*, *E. necatrix* [2] ]Among them, *E. aceroulina*, *E. necatrix*, *E. tenella*, *E. maxima*, and *E. brunetti* are the major species infecting chickens. The parasites invade and develop inside the intestinal epithelial cells of chickens, causing the intestinal barrier destruction which leads to bloody feces excretion, reduction of feed intake, weight losses, and death in case of heavy infections, leading to massive economic losses to the farmers (Zaman *et al.*, [3]).

---

Corresponding: [thuydungty42@gmail.com](mailto:thuydungty42@gmail.com)

Submitted: December 11, 2018; Revised: January 08, 2019; Accepted: January 22, 2019

Thua Thien Hue province is located in the central part of Vietnam with a tropical monsoon climate, where coccidiosis, as the rule, occurs frequently. According to the observation in the farms in Thua Thien Hue province, there is a high rate of chickens with the symptoms of coccidiosis such as weight loss and bloody feces excretion. However, the information of pathogenicity of *Eimeria* species is still limited in Vietnam, particularly in the central area. The present study is, therefore, to reveal the effects of coccidiosis on chickens, which may be useful for coccidiosis diagnosis and prevention. In addition, this information is considered as a reference to compare with the database of pathogenicity of *Eimeria* species in other countries around the world.

## 2 Materials and methods

### Isolation of *Eimeria* oocysts

*Eimeria* oocysts were isolated from collected dropping which clinically diagnosed to be infected with coccidiosis from 3 farms in Huong Thuy district, Thua Thien Hue province using the flotation method with saturated saccharose. The oocysts were then kept for sporulation in a 2.5% potassium dichromate solution at room temperature for 2 days and stored at 4 °C till use (Rosa et al., [11]).

### *Eimeria* infection

A total of 70 3F-Viet 103 chicks 2-dayold were purchased from a commercial company and raised for 2 weeks in our facility. 54 chicks were chosen and randomly allocated to 2 treatments: *Eimeria* treated group and control group. The experimental units were repeated 3 times with 9 chicks each. Isolated oocysts were used for *Eimeria* infection. For use, the potassium dichromate solution was washed out with distilled water by centrifugation twice (2500 rpm), and the number of oocysts were then counted in a McMaster chamber using light microscopy (Foreyt et al., [4]). The chicks in group 1 and 2 were orally inoculated with 1 mL of  $2 \times 10^4$  *Eimeria* sporulated oocysts and PBS, respectively.

### Oocyst output

Feces were collected daily from *Eimeria* treated chicks and control chicks from 5 to 15 days after infection. The feces in each cage were mixed thoroughly, then 2 grams of feces per each cage was collected and put into 15 mL centrifuge tubes and kept in a refrigerator until counting using the McMaster chamber (Long et al., [1]).

### Growth performance

Feed intake, body weight, and body-weight gain were weekly measured individually in the morning before feeding using an electronic scale.

### Gross lesions and Histopathological lesions

Three chickens per treatment were sacrificed at 5, 10 and 28 days after *Eimeria* inoculation using the cervical dislocation method. Collected ceca were fixed for 24 hours in 10% formalin. A 3–5 mm disk from the middle part of the cecum was cut, embedded in paraffin. It was cut at the cross-sections at a thickness of 6  $\mu\text{m}$  with a microtome and stained with Hematoxylin and Eosin (HE). Five cross-sections per chicken were then examined using a light microscope.

### Data analysis

The data of growth performance including feed intake, body weight, and body-weight gain were analyzed using Microsoft Excel 2007 and Minitab 16.2.3.0. Paired t-tests were conducted to compare the control and the *Eimeria* treated groups. A probability value of  $p < 0.05$  was considered to be statistically significant.

## 3 Results

### 3.1 Oocyst output

As can be seen in Figure 1, the *Eimeria* treated chickens discharge the oocysts for 9 days (from 6 to 14 days after infection). The number of oocysts is highest at 8 days post-infection (dpi), then gradually reduces until finish at 14 dpi, while no oocysts are detected in control chickens.

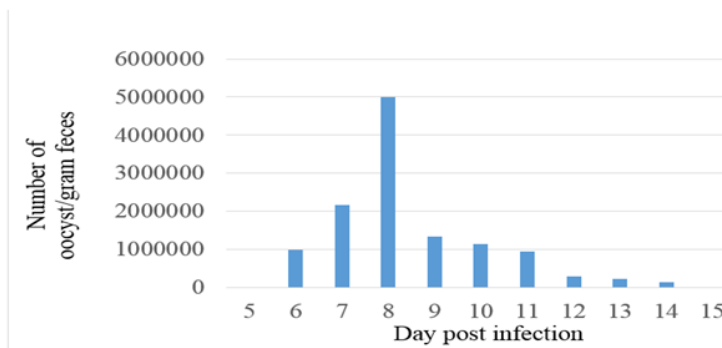


Figure 1. Fecal oocyst output

### 3.2 Gross lesions

The results show that ceca are the most damaged part of the gastro-intestinal system of *Eimeria* treated chickens. The ceca of infected chickens are damaged with a large amount of blood in the ceca content at 5 dpi. Then, they seem to recover without bleeding, but the chickens still suffer from diarrhea at 10 dpi. The ceca slightly thicken at 28 dpi. Meanwhile, the ceca of control chickens are in normal condition.



Figure 2. Morphological changes in ceca during *Eimeria* infection

### 3.3 Growth performance

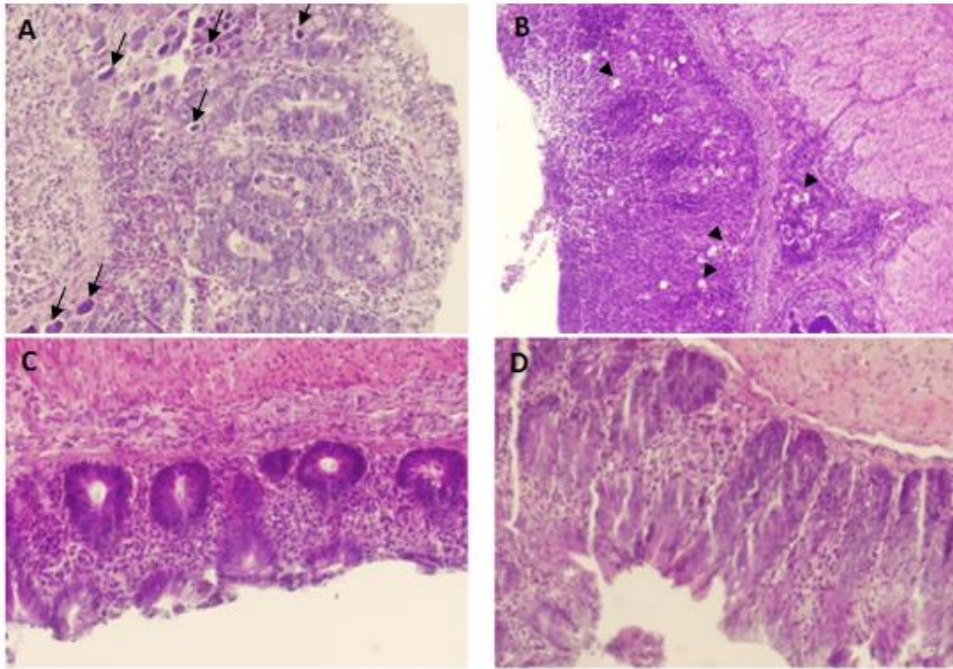
Overall, the tendency of growth performance including feed intake, body-weight gain, and body weight is lower in infected chickens than that in the control in this experiment. Among them, the feed intake is statistically significantly higher in control than in treated chickens at 6 weeks. The body weight of treated chickens is also significantly lower than that in control at 5 and 6-week-old (Table 1).

**Table 1.** Growth performance of chickens

Age (week)	Group 1 (Infected)	Group 2 (Control)	<i>p</i>
<b>Feed intake (gram/broiler/week)</b>			
4	241,33 ± 9,01	257,67 ± 5,51	0,056
5	329,67 ± 45,08	374,33 ± 16,07	0,181
6	490,00 ± 20,00	610,00 ± 47,32	0,016
7	728,7 ± 55,30	873,70 ± 194,90	0,283
<b>Body weight gain (gram/broiler/week)</b>			
4	84,76 ± 35,16	116,33 ± 16,65	0,231
5	105,33 ± 38,55	134,00 ± 18,33	0,309
6	142,33 ± 8,74	180,33 ± 29,01	0,096
7	161,00 ± 65,55	172,67 ± 67,52	0,840
<b>Body weight (gram/broiler)</b>			
3	328,67 ± 3,79	325,00 ± 18,03	0,231
4	413,33 ± 31,39	441,33 ± 9,07	0,212
5	518,67 ± 11,15	575,33 ± 14,36	0,006
6	661,00 ± 19,08	755,67 ± 41,19	0,023
7	822,00 ± 84,5	928,00 ± 107,8	0,250

### 3.4 Histopathological lesions

At 5 dpi, there is a large amount of *Eimeria* in the second schizonts (Picture A, arrow). They are detected from the cross-sections of the infected chickens. As a consequence, the high number of infiltrated inflammatory cells and mucosal destruction are seen in the *Eimeria* treated group (Picture A) as well. At 10 dpi, the oocysts are observed in the mucosal area of ceca of the infected chickens (Picture B, arrowhead). Furthermore, the normal structure of crypts at 10 dpi is also damaged compared with the control.



**Figure 3.** Histopathological lesions in the ceca of chickens by HE staining

A: *Eimeria* treated 5 dpi; B: *Eimeria* treated 10 dpi; C: Control 5 dpi; D: Control 10 dpi

Arrow: *Eimeria* in second schizont stage; Arrowhead: Oocyst of *Eimeria*

#### 4 Discussion

The chickens infected with mixed *Eimeria* species show the general symptoms of coccidiosis infection. They have ruffled feathers and anorexia, huddling together with loose dropping and/or bloody dropping from 4 to 7 days post-infection (data not shown). In the north of Vietnam, there are 6 reported species of *Eimeria*, including *Eimeria tenella*, *E. aceroulina*, *E. brunetti*, *E. maxima*, *E. mitis*, and *E. necatrix*. Among them, *E. tenella* species are prevalent (96,55%) [9]. The present experiment reveals that *E. tenella* is also the dominant species in the central of Vietnam because the ceca are the most damaged part of the intestine which is reported as the specific site of *E. tenella* development. The dominant prevalence of *Eimeira tenella* among *Eimeria* species is also reported in China, India, Saudi Arabia, Sudan (Lan et al., [5], Thenmozhi et al., [6], Al-Quraishy et al., [7], Sudan et al., [8]).

The isolated *Eimeria* species from central Vietnam shows a high virulence. The evidence consists of the reduction of feed intake, body weight and body-weight gain in *Eimeria* treated chickens compared with those in the control. In addition, the ceca of infected chicks are destructed due to the proliferation and movement of *Eimeria* in endogenous stages

(Emilio et al., [10]). Consequently, the ceca contain a large amount of blood in the cecal content at 5 dpi. The tissue destruction has also been observed clearly in the HE sections with massive infiltrated inflammatory cells (Figure 3).

The farmers usually diagnose coccidiosis according to the presence of blood in the stool because it is difficult to test the presence of oocysts in the fecal samples in their farm facilities. Generally, the farmers may consider that chickens recover when they stop excreting blood in the stool. However, the results in the present study show that although there is no blood in the feces (from 8 to 14 dpi), a large number of oocysts are still shedding (Figure 1). Because the parasites first invade the host epithelium cells and undergo 3 times of schizont formation which contains about 900, 350, 16 merozoites, respectively. The development and movement of the schizonts last for 5–6 days, causing tissue destruction and the presence of blood in the feces. After that, the immature oocysts have been formed in the reproduction stages and discharged to the environment along with feces (Matsubayashi et al., [12]). Therefore, periodic vaccination is necessary for the coccidiosis control in the farms. Besides, collecting and treating the feces of infected chickens at an appropriate time and manner greatly contribute to limiting the spread of this disease.

## 5 Conclusion

In this study, the effect of locally isolated *Eimeria* species on chickens in Thua Thien Hue province has been identified. The development of *Eimeria* species greatly damages the intestinal system of infected chickens and leads to bleeding, particularly at 5 days after infection. Therefore, infected chickens reduce feed intake, growth performance, and body weight. After the complete development in host epithelial cells, the parasites then spread to the environment together with feces in the oocyst form. Oocysts can survive in the environment for a long time and affect healthy chickens via food and water intake. The present study provides useful information related to the pathogenicity of *Eimeria* species and contributes to the coccidiosis diagnosis and treatment in poultry production.

## References

1. Long, P. L., Joyner, L. P., Millard, B. J. and Norton, C. C., (1967), *A guide to laboratory techniques used in the study and diagnosis of avian coccidiosis*, *Folia Veterinaria Latina*, 6, 201–217.
2. Joyner, L. P. and Long, P. L., (1974), The specific characters of the *Eimeria*, with special reference to the coccidia of the fowl, *Avian Pathology*, 3(3), 145–157.
3. Zaman, M. A., Iqbal, Z., Abbas, R. Z. and Ehtisham-Ul-Haque, S., (2015), In vitro Efficacy of Herbal Extracts against *Eimeria tenella*, *Int. J. Agric. Biol*, 1560–8530.
4. Foreyt, B., (2001), *Veterinary Parasitology Reference Manual*, Iowa State University Press, Ames, Iowa, USA.
5. Lan, L. H., Sun, B. B., Zuo, B. X., Chen, X. Q. and Du, A. F., (2017), Prevalence and drug resistance of avian *Eimeria* species in broiler chicken farms of Zhejiang province, China, *Poultry Science*, 96(7), 2104–2109 .
6. Thenmozhi, V., Sairabanu, S., Selvarani, R., Raman, M., Gomathinayagam, S. and Dhinakar, G. R., (2013), Prevalence of Avian *Eimeria* Species in Commercial Poultry in Southern India, *Indian Vet. J*, 90(11), 24–25.
7. Al-Quraishy, S., Abdel-Baki, A. S. and Dkhil, M. A., (2009), *Eimeria tenella* infection among broiler chicks *Gallus domesticus* in Riyadh city, Saudi Arabia, *Journal of King Saud University (Science)*, 21, 191–193.
8. Sudan, A. A. and Ghada, H. A., (2017), *Eimeria* Spp. Infection in Some Broiler Farms in Khartoum State, *SOJ Veterinary Sciences*, 1–3.
9. Hoan, T. D., Javaid, A. G. and Riaz, A. L., (2014), Molecular identification of *Eimeria* species infection in chickens in surrounding areas of the red river delta in Vietnam, *International Journal of Livestock Research*, 4(7), 9–18.
10. Emilio, C., Margarita, G., Lillehoj, H. S., Joaquín, Q., Erik, P. L., Ana, R. and Caridad, S. A., (2014), Il-17A regulates *eimeria tenella* schizont maturation and migration in avian coccidiosis, *Vet Res*, 45(1), 1–9.
11. Rosa, E. Q. C., and Edgar, D. G., (2015), *Control of Avian Coccidiosis, Future and Present Natural Alternatives*, BioMed Research International, 1–11.
12. Matsubayashi, M., Hatta, T., Miyoshi, T., Alim, M.A., Yamaji, K., Shimura, K., Isobe, T. and Tsuji; N., (2012), Synchronous development of *Eimeria tenella* in chicken caeca and utility of laser microdissection for purification of single stage schizont RNA, *Parasitology*, 139(12), 1553–1561.